

Original Research Article

EXPERIENCE WITH THE USE OF AORTA CLAMP ON EFFECTIVENESS AND SAFETY DURING CESAREAN HYSTERECTOMY IN PLACENTA ACCRETA SPECTRUM AT A TERTIARY CARE CENTRE

Ponnuru Malathi¹, Pulletikurti Chandralekha², Nuthalapati Venkata Naga Praneeth³, B.Krishna Kishore⁴, Kuthadi Swarupa⁵, P.Rajini Reddy⁶, Madhulatha Alexander⁷, Renuka.P⁸, Alagandala Anuradha⁹

¹Professor, Department of Obstetrics and Gynaecology, Modern Government Maternity Hospital, Osmania Medical College, Petlaburz, Hyderabad, Telangana, India.

²Postgraduate, Department of Obstetrics and Gynaecology, Osmania Medical College, Hyderabad, Telangana, India.

³Post Graduate: Department of Urology, Osmania Medical College, Hyderabad, Telangana, India.

⁴Assistant Professor, Department of Cardio Thoracic and Vascular Surgery (CTVS), Osmania Medical College, Hyderabad, Telangana, India.

⁵Associate Professor, Department of Obstetrics and Gynaecology, Modern Government Maternity Hospital/Osmania Medical College, Petlaburz, Hyderabad, Telangana, India.

⁶Professor, Department of Obstetrics and Gynaecology, Modern Government Maternity Hospital/Osmania Medical College, Petlaburz, Hyderabad, Telangana, India.

⁷Professor, Department of Obstetrics and Gynaecology, Modern Government Maternity Hospital/Osmania Medical College, Petlaburz, Hyderabad, Telangana, India.

⁸Professor: Department of Obstetrics and Gynaecology: Modern Government Maternity Hospital/Osmania Medical College, Petlaburz, Hyderabad, Telangana, India.

⁹Professor, Department of Anaesthesiology, Modern Government Maternity Hospital/Osmania Medical College, Petlaburz, Hyderabad, Telangana, India.

Received : 17/10/2024
Received in revised form : 08/12/2024
Accepted : 23/12/2024

Corresponding Author:

Dr. Ponnuru Malathi,
Professor, Department of Obstetrics and Gynaecology, Modern Government Maternity Hospital/ Osmania Medical College, Hyderabad, Telangana, India.
Email: malathiponnuru@gmail.com

DOI: 10.70034/ijmedph.2024.4.240

Source of Support: Nil,
Conflict of Interest: None declared

Int J Med Pub Health
2024; 14 (4); 1312-1318

ABSTRACT

Background: With alarming rise in cesarean births in the State of Telangana there is proportional increase in Placenta Accreta Spectrum (PAS). Advanced cases of PAS are managed by primary Cesarean Hysterectomy (CH). To overcome the complications while performing CH, in advanced PAS cases we propose to use the novel dissection free Paily aorta clamp (PAC) with inbuilt safety features to clamp the distal end of aorta. **Aim:** In this study we propose to assess the effectiveness of PAC in terms of intraoperative blood loss, need for blood component and safety in terms of intraoperative and postoperative clamp related complications.

Material and Methods: This study is a retrospective review of 17 cases of histologically confirmed advanced PAS where PAC was applied by a single trained provider at a single tertiary public care centre of Telangana over a period of thirteen months.

Results: A total of seventeen women with varying grades of PAS, underwent either subtotal or total Caesarean hysterectomy using PAC. Most of the women in study are in 20-25 years age group with 2 previous Caesarean sections. Planned sections were more. Median estimated blood loss was 1.5L+/-500ml. The estimated intra-operative blood loss (EBL) of > 2 liters were 8 cases. 3 cases did not require any transfusion and none required massive transfusion. The total number who (n =14 /17) required blood transfusions, the minimum units were 2 and the maximum units were 7. The median application time of Aorta Clamp was 25 minutes+/-5min -- the minimum time was -15 minutes and maximum time was 42 minutes. There was no associated visible clamp site injuries like tears, bleeding, haematomas or ecchymosis. The return of circulation (ROC) was immediate on release of the clamp. There was no associated distal thromboembolic events or symptoms related to bowel ischemia in the post-operative period or during follow up.

Conclusion: PAC is found to be both safe and an effective promising tool in the armamentarium of the trained obstetrician in managing PAS cases.

Key Words: Placenta Accreta Spectrum, Aorta Clamp, Armamentarium, Intra-operative blood loss.

INTRODUCTION

As per Government of India Ministry of Health and Family Welfare Statistics Division Health Management (HMIS) 2020-2021 and 2021-2022 Analytical Report In India -

Total of 20.5 % of caesarean section deliveries is reported in 2019-2020. In 2020-21 it increased to 21.3% and 23.29% in 2021-22. The trends show that highest percentage of Caesarean section deliveries from Telangana -55.33% in 2020-2021 and 54.09% in 2021-2022. As per special bulletin on maternal mortality in INDIA 2018-20, SRS the Maternal mortality ratio in Telangana is 43 and maternal mortality rate is 2.3.^[1]

If caesarean rates continue to increase, the annual incidence of placenta previa, placenta accreta, and maternal deaths will also rise substantially.^[2] Rising Caesarean births thereby proportionate increase in PAS cases and need for primary CH is observed in Telangana State.

Hysterectomy remains the definitive surgical treatment for PAS disorders, especially for its invasive forms, and a primary elective caesarean hysterectomy is the safest and most practical option for most low- and middle-income countries where diagnosis, follow-up, and additional treatments are not available.^[3]

Placenta accreta can lead to haemorrhage, resulting in hysterectomy, blood transfusion, multiple organ failure, and death.^[4] Minimising the massive bleed during CH can prevent most of the complications related to CH and thereby maternal morbidity and mortality.

Degree of placenta accreta invasion, number of prior caesarean deliveries and intraoperative blood loss were associated with a higher likelihood of urologic injury.^[5] Hence to avoid urinary tract injuries, major intraoperative bleed must be minimised and clear operative field must be facilitated to the operating surgeon.^[5,6,7] To overcome the above mentioned complications in managing PAS during CH we propose to use the novel dissection free Paily aorta clamp (PAC), specially designed for use by the obstetricians in low resource settings during CH for cases of PAS . We describe our experience on safety and efficacy with Paily Aorta clamp application in managing PAS cases done by single trained provider at single tertiary public centre, the first institute in the State to use the clamp.

MATERIALS AND METHODS

Modern government Maternity Hospital (MGMH) is one of the biggest public referral hospital the only centre using Paily Aorta Clamp in the entire Telangana state. This is the clinical outcome of 17

cases of advanced PAS managed with PAC between June 2023 to July 2024. Both planned and emergency Caesarean Hysterectomy (CH) done for advanced PAS is included in the study. 3 cases of minor grade of PAS managed conservatively without PAC is excluded from this case series. One case who underwent emergency CH by the available duty team without considering application of PAS is not included in the series but being mentioned as PAC was applied post CH to facilitate the urologist to secure haemostasis at bladder base. Institutional Ethics Committee clearance by Osmania Medical College , Hyderabad , Telangana , India approved this study in September 2024. Diagnosis of PAS was made antenatally by Grey Scale ultrasound ,MRI and Doppler in all planned cases . Grade of PAS is classified as per FIGO guidelines and histologic confirmation.

Description of PAILY AORTA CLAMP

It is a simple straight instrument with blunt overlapping tips to prevent slipping of aorta ,the smooth inner surface with 2mm gap between the blades even on maximum closure prevents crush injury to the vessel wall and vaso-vasorum of the aorta. The distal ratchet is provided with multiple serrations for clamping. [Figure 1, 2 & 3]

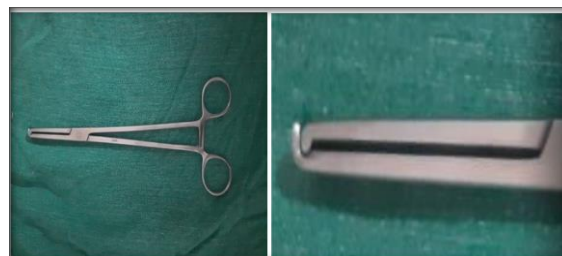

Figure 1 & 2: Closed PAC - Blunt overlapping tips with a gap of 2mm between the blades

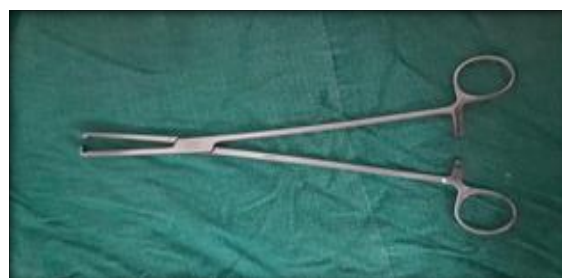

Figure 3: Open PAC with smooth inner surface.

Informed written consent and video counselling is taken in all cases undergoing CH with PAC application. The need for surgery, risks involved ,benefits of Aorta clamp like minimising blood loss, lesser need for massive transfusion, lesser chances of lower urinary tract injuries ,the likely complication with the instrument and the necessary precautions

that will be taken to minimise the complications is explained. Need for midline incision extending above the umbilicus to expose the aorta is explained.

Elective procedures were scheduled between 34 - 36 weeks of gestation, emergency procedures were done based on the clinical situation. Antenatal corticosteroid injection Dexamethasone for lung maturation is given when delivery was planned before 37 0/7 weeks of gestation and is consistent with current gestational age-based ACOG recommendations.^[6]

Standard care plan

Preoperative preparation

Optimising haemoglobin levels using parenteral iron, preoperative shower to minimise surgical site, infection is done in scheduled cases.

Prophylactic antibiotic is given 30 minutes before the procedure. Ureteric stenting is done in suspected or confirmed cases of bladder invasion.

Blood components arranged in anticipation of massive bleed – 4 units of each packed Red Blood Cells (pRBC), Fresh Frozen Plasma (FFP) and Random or Single donor platelets (RDP, SDP). To prevent Deep Vein Thrombosis (DVT) prophylactic Intermittent pneumatic compression device is used. Multidisciplinary team consisting of two senior obstetricians, two obstetric residents, one senior and two junior anaesthetists, two trained nursing officers, one blood bank officer, one Urologist and one CT surgeon.

Women are prepared in supine position with left lateral tilt, placed under combined spinal with epidural anaesthesia or general. Indwelling triple lumen Foleys is used to catheterise the bladder. Subcutaneous low molecular weight heparin is given for 3 days in the postoperative period.

Surgical technique

We approached by vertical midline skin incision and extended supraumbilical to facilitate vertical placement of Aorta Clamp without any angulation. The lower segment is assessed for its vascularity, bulge sign, lateral invasion and bladder location.

Either transfundal transverse incision between the two round ligaments or midline vertical uterine incision above the level of the placenta is taken. Bleeding from the edges of the uterine incision is secured with Green Armytage and Paily T clamp. (Figure- 4) Fetus is delivered by breech extraction. Delayed clamping of the cord is practised, early breast feeding initiated in all feasible situations, the free end of cord tied with black silk and replaced into the uterine cavity. Inj. Tranexamic Acid 1gm in 100ml normal saline is administered in advanced cases of PAS after clamping of the cord.

We wait for few minutes to watch for spontaneous placental separation, no attempt is made to separate the placenta manually except one attempt of gentle traction to check on adherence. If no separation of placenta happens or if dimple sign is noted on gentle traction indicating adherence we proceed with CH with placenta in situ. Closure of transfundal incision in single layer using 0-Vicryl is done before

proceeding for CH. (Figure-5) Uterotonics is not administered as they can cause partial separation of placenta and promote bleeding.

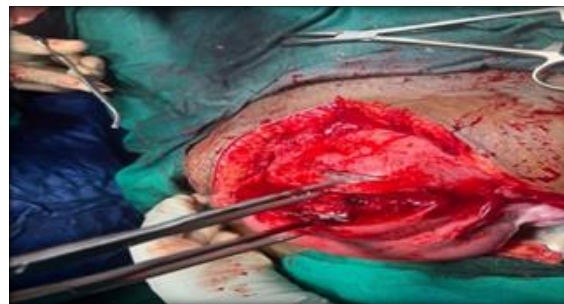


Figure 4: Uterine cut edges held with Paily Haemostatic T Clamp

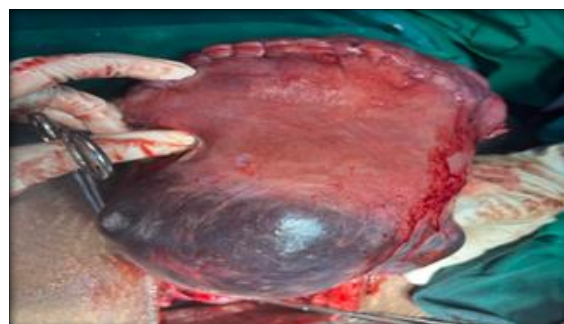


Figure 5: Sutured transfundal uterine incision with bluish placental bulge.

The uterus is exteriorised and pushed caudally by the assistant taking care not to disturb the coagulum or placental bulge. (Figure- 5) Upper pedicles that is round ligaments and Tubo ovarian ligaments on both sides clamped, cauterised and sutured before application of the Aorta clamp as these two upper pedicles is away from the hypervascular placental bed. Lateral straight or curved clamps to hold the uterus is avoided and uterus is held manually.

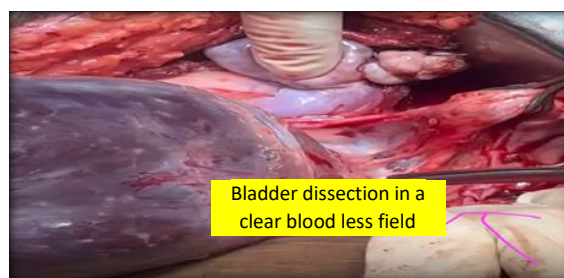


Figure 6: Post PAC application Bladder dissection in a clear bloodless field

Bowels packed on both sides using saline soaked mops and held in place with large sized Daevers retractors. The lower end of abdominal aorta identified by palpation. Using a Babcock forceps aorta is gently lifted up and held in that position till aorta clamp is placed. Call out time by operating surgeon on application of aorta clamp is noted by the anaesthetist. The retroperitoneal dissection free PAC is applied under good vision without any angulation

making sure that the entire wall of aorta is between the blades.

The instrument is provided with multiple serrations at the ratchet but minimum required occlusive clamping force is used that is adequate to stop the pulsations in the common iliac arteries on both the sides. Babcocks is released only after confirming this step to avoid repeated holding of aorta. The clamp is stabilised in position by one of the team members all through the procedure to avoid accidental pull or dislodging of the aorta clamp.

The highly vascular and fragile lower segment is dealt only after applying the Aorta clamp in a clear blood less operative field (Figure-6). Haemostasis is secured by ligating larger bridging vessels using right angle instrument and smaller vessels by coagulation. After securing the bridging vessels if any, we proceed with sharp dissection of the bladder

Intraoperative estimated blood loss (EBL) is assessed periodically by the anaesthetist. The decision on blood component transfusion is taken by the senior anaesthetist after discussing with the operating surgeon. Gravimetric evaluation of intraoperative blood loss was found to be an accurate method, which can be recommended for use in a clinical setting.^[7,8]

To avoid underestimation of EBL, blood collected in the suction containers, calculation of mops by gravimetric method and visual estimation of soaked drapes and floor spills is used to calculate total EBL.

1. The amount of blood collected in suction containers
2. Gravimetric method the weight of blood-soaked surgical pads (1gm = 1ml)
3. visual estimation of blood spilled over the floor, if any.

The sucked blood and the amniotic fluid before application of the clamp was noted and subtracted from the total EBL at the end of the procedure to estimate the exact blood loss post clamp application. Postoperatively haemoglobin was estimated with in first 24 hours.

The decision to perform total vs subtotal hysterectomy is decided based on the finding of feeling of lower edge of the placenta by compressing the anterior and posterior walls of the lower segment, between the fingers. After transversely clamping and transecting the cervix the edges are held with long Allis forceps and inspected to ensure if lower edge of placenta is removed. The specimen is cut to reconfirm complete removal of placenta.(Figure- 9) This step is crucial to prevent post-operative haemorrhage and re laparotomy. Vault or cervix is closed using box sutures.

Aorta clamp is released under vision and bladder base is checked for any brisk bleeding(Figure-7). If brisk bleeding is noticed immediate reclamping of Aorta is done. Ligation of the bleeders is attempted first if not controlled internal iliac artery ligation is attempted by the urologist. Call out time on release of the aorta clamp is noted by anaesthetist and total clamp time is calculated. Once the clamp is released Aorta is massaged for few seconds to relieve the spasm.

Return of circulation (ROC) is confirmed by palpating common iliacs on both sides (Figure _8) The site of clamping is inspected for any tears, bleeding, haematomas or ecchymosis.

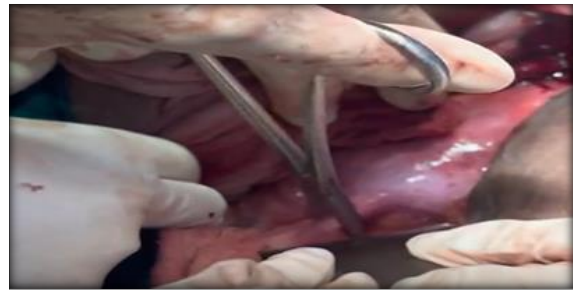

Figure 7: Release of PAC from distal aorta under vision

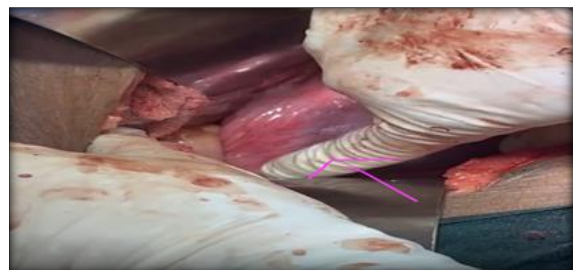

Figure 8: Post release of clamp site. Checking for ROC in Common Iliacs.

Bladder integrity test is done at the end of CH in difficult cases of bladder dissection. All cases are monitored in ICU for next 24 -48 hrs and then stepped down to HDU.

The cut specimen is sent for histopathology and the final grade of PAS is confirmed.

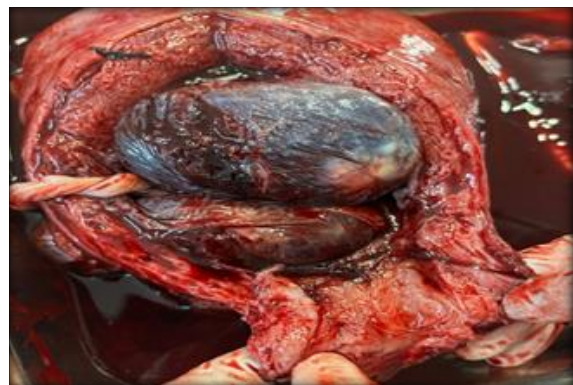


Figure 9: Cut section showing complete removal of lower placental edge

Statistics

(Distribution of nominal variables will be reported with frequency (percentage) and Pearson's χ^2 tests, whereas continuous variables will be reported with mean \pm S.D and one-way ANOVA (or median \pm IQR and Kruskal Wallis as specified), when the cases were classified according to their final PAS grades. A value $p < 0.05$ was accepted as the threshold for statistical significance. All statistical analysis was performed on SPSS version 25 (IBM, Armonk, NY, USA)

RESULTS

The required maternal baseline characteristics, intraoperative ,peri-operative outcomes and histopathological reports are abstracted from the records and summarised in tables 1 and 2.

Most of the women in study are in 20-25 years age group with 2 C sections. Planned sections were more. Total Caesarean Hysterectomy was required more than that of subtotal CH. [Table 1]

The estimated intra-operative blood loss (EBL)of > 2 liters were 8 cases . 3 cases did not require any transfusion and none required massive transfusion. The total number who (n =14 /17) required blood transfusions, the minimum units were 2 and the maximum units were 7.

Median transfusion components required were 3 ± 2 units of p RBC, 3+1 --units of fresh frozen plasma (FFP).None required cryoprecipitate or platelet transfusion. The preoperative and post-operative difference in haemoglobin in 3 women who did not receive blood transfusion was between 1-1.3 g %. [Table 2]

Time of Aorta Clamp-minimum time was -15 minutes and maximum time was 42 minutes. One woman (case 17) of advanced PAS with left parametrial invasion required reclamping to manage active bladder base bleed .Bleeding was controlled successfully by ligating the bleeders without the need for internal iliac artery ligation with clamp time of 28 minutes. Our study had 10 cases of PAS of grade 2 and 7 cases of PAS of grade 3. [Table 3]

One woman (case 6) suffered injury of the bladder dome while dissecting the densely adherent bladder. It was promptly identified and repaired by urologist. With this experience to avoid bladder injuries, dissection was attempted after partially filling the bladder whenever densely adherent bladder was suspected. There was no case of ureteric injury.

One woman (case 17) Late referral at 33weeks for advanced PAS with left parametrial invasion. She had evidence of scar pregnancy in scan done at early weeks ,but was not counselled on PAS or given an option of termination .Reclamping of PAC was required to manage active bleed from bladder base .Bleeding was controlled successfully by ligating the bleeders without the need for internal iliac artery ligation.

One maternal death (case 14) underwent an emergency CH at odd hours by the available duty team for antepartum haemorrhage without considering aorta clamp application at the time of CH. The intraoperative EBL was around 3200ml leading to class 4 haemorrhagic shock. Aorta clamp was applied post CH to tackle the brisk bleeding from the bladder base. It was a deviation from the standard care plan.

None of the women developed any signs of aortic wall tear, bleeding, haematomas, ecchymosis, reperfusion injury, lower limb thromboembolic phenomenon or abdominal-pelvic organ ischemia in the immediate post-operative period (3 days) and between 4 - 6th week of follow-up visit. One women was lost to follow-up who was a migrant labourer. [Table 3]

Table 1: Maternal pre-operative demographics

Maternal age	Number of patients	Percentages
20-25yrs	8	47.06
26-30 yrs	6	35.29
31-35yrs	3	17.65
No of previous C sections		
1	4	23.53
2	9	52.94
3	4	23.53
Gestation age in weeks		
28-32wks	5	29.41
33-36wks	8	47.06
>36wks	4	23.53
Planned /Emergency CH		
Planned	15	88.24
Emergency	2	11.76
Caesarean Hysterectomy		
Total CH	9	52.94
Subtotal CH	8	47.06

Table 2: Estimated blood loss and Number of blood products transfused

Estimated blood loss	Number of patients	Percentages
<500ml	1	5.88
500-1000ml	2	11.76
>1000ml -1.5lts	3	17.65
>1.5lts -2lts	3	17.65
>2lts -2.5lts	8	47.06
Transfusions		
No transfusion	3	17.65
2components	4	23.53
>2- 4	5	29.41

>4 -7	5	29.41
8 or >	Nil	
Cryo ,Platelets	Nil	

Table 3: Aorta clamp duration /Reclamping

Clamp duration / Reclamping	Number of patients	Percentages
15min	1	5.88
16-30min	15	88.24
>30min -45 min	1	5.88
Reclamping	1	5.88

Table 4: Post-operative surgical outcomes of PAC

Complications	Number of patients	Percentages
Bladder injury	1	

DISCUSSION

Total of 17 women of PAS with grade 2 (10 cases) and grade 3 (7 cases) managed using dissection free PAC ,by following the institution laid standard plan. All of them had expected surgical outcomes with no clamp related complications.

The estimated intra-operative blood loss (EBL)of > 2 liters were 8 cases . 3 cases did not require any transfusion and none required massive transfusion. The total number who (n =14 /17) required blood transfusions, the minimum units were 2 and the maximum units were.^[7]

Median transfusion components required were 3 ± 2 units of p RBC, 3 ± 1 --units of fresh frozen plasma (FFP).None required cryoprecipitate or platelet transfusion. The preoperative and post-operative difference in haemoglobin in 3 women who did not receive blood transfusion was between 1-1.3 g %.

Globally massive haemorrhage is tackled by various modalities which require greater skill and resources .One such strategy is - placement of inflatable balloons within the pelvic arteries, most commonly in the anterior divisions of the internal iliac arteries. As per the results of various studies ,these prophylactic balloons does not seem to be promising as women undergoing prophylactic placement of endovascular balloons at caesarean hysterectomy for PAS disorders had a 10.6% procedure-related complication rate and increased total procedure time, with no decrease in blood loss compared to those undergoing surgical ligation.^[8,9,10,11]

Another commonly practised procedure to minimise the massive bleed is ligation of internal iliac artery which needs retroperitoneal dissection. The results of this procedure was found to have variable results in reducing blood loss.

As per Nieto-Calvache, Albaro José et al - Consistent with previous physiologic research that described a broad collateral pelvic arterial network, several expert consensus and international guidelines have reported that internal iliac artery (IIA)occlusion is not fully efficacious for the management of PAS. Several controlled clinical trials and systematic reviews have reported the low efficacy of this procedure.^[12]

Though IIA ligation procedure for minimising bleeding during CH for advanced cases of PAS remains controversial ,if need arises like brisk bleed from bladder base post clamp release, either the obstetrician or the urologist should be able to perform IIA ligation.

As per the authors John C. Kingdom, Sebastian R. Hobson et al on minimising blood loss during CH in dealing with superior devascularization advocate on traditional suture ligation and the principal risk of bleeding is from excessive upward traction on the uterus by lateral straight clamps, rather than by manual elevation.^[10]

In our study PAC was applied after the step of superior devascularization, that is ligation of both round and tubo ovarian ligaments .The uterus was manually elevated by the assistant use of lateral curved or straight clamps to stabilise the uterus was avoided. By doing so we could minimise the aorta clamp time as well as avoided any inadvertent bleeding happening from excessive traction of the lateral clamps by the assistant if used.

The atraumatic features of PAC, the dissection free application and the preperitoneal fat probably acting as a protective cushion all together eliminate the risk of injury to inferior vena cava and posterior lumbar vessels.

Following the right technique of application by grasping the entire aortic wall without any angulation is equally important to avoid injury to aorta.

The clear operative field facilitates the surgeon to operate with precision and confidence.

Similar positive outcomes with no vascular injury so far is reported in the case series of 15 women who underwent CH for PAS using aorta clamp at KEM Hospital, Pune, India.^[13] and 33 women of varying grades of PAS managed at Rajagiri Hospital - Kerala, India.^[14]

Cases managed by following the standard care plan had positive outcomes and no clamp related vascular injury. Peer group feedback within the institute was positive and expressed their willingness to get trained.

CONCLUSION

PAC is found to be both safe and effective promising tool in the armamentarium of the trained obstetrician in managing PAS cases, in terms of minimising blood loss, limiting the need for massive transfusion, facilitating clear operative field for the surgeon to operate with precision and confidence in dealing with the most crucial step of bladder dissection and most importantly with significant reduction in maternal morbidity and mortality.

Retroperitoneal dissection free PAC appears to be the most appropriate strategy in dealing with advanced cases of PAS by a trained obstetrician in resource limited settings.

Obstetricians managing this complex pelvic surgery must get trained on Aorta clamp application as positive outcomes are observed from various centres in INDIA using the clamp including our centre.

Acknowledgements

This study is possible because of the support of the State government officials of Telangana in facilitating training, trainer Dr Paily, referral centres, women under our care, colleagues from the departments of Obstetrics, Anaesthesiology, Radiology, Urology, Cardiothoracic-Vascular Surgery, Pathology, Blood bank, Junior and senior residents of our department. We are also grateful to the Institutional ethics committee, support given by Medical Superintendent of Osmania General Hospital, nursing officers and support staff of Modern Government Maternity Hospital Hyderabad Telangana.

Contributions: The multidisciplinary team consisting of:

Dr. Ponnuru Malathi – Professor of OBGYN, Osmania Medical College

Dr. A. Anuradha- Professor of Anaesthesiology, Osmania Medical College

Dr. K. Swarupa- Associate professor of OBGYN, Osmania Medical college

Dr. Venkata Naga Praneeth-Urologist, Osmania Medical College

Dr, Krishna Kishore- Cardiothoracic-vascular surgeon, Osmania Medical College

Dr. P. Chandralekha – Postgraduate OBGYN, Osmania Medical College

Team of Professors who contributed cases for the study-(5 cases)

Dr. Rajini Reddy

Dr. Madhulatha Alexander

Dr. Renuka. P

REFERENCES

1. Government of India Ministry of Health and Family Welfare Statistics Division Health Management (HMIS) 2020-2021 and 2021-2022 Analytical Report.
2. Solheim KN, Esakoff TF, Little SE, Cheng YW, Sparks TN, Caughey AB. The effect of cesarean delivery rates on the future incidence of placenta previa, placenta accreta, and maternal mortality. *J Matern Fetal Neonatal Med.* 2011 Nov;24(11):1341-6.
3. Allen L, Jauniaux E, Hobson S, Papillon-Smith J, Belfort MA; FIGO Placenta Accreta Diagnosis and Management Expert Consensus Panel. FIGO consensus guidelines on placenta accreta spectrum disorders: Nonconservative surgical management. *Int J Gynaecol Obstet.* 2018 Mar;140(3):281-290.
4. Silver RM, Barbour KD. Placenta accreta spectrum: accreta, increta, and percreta. *Obstet Gynecol Clin North Am.* 2015 Jun;42(2):381-402.
5. Woldu SL, Ordonez MA, Devine PC, Wright JD. Urologic considerations of placenta accreta: a contemporary tertiary care institutional experience. *Urol Int.* 2014;93(1):74-9.
6. Yasser Y. El-Sayed, MD, Ann E.B. Borders, MD, MSc, MPH, and the Society for Maternal-Fetal Medicine's liaison member Cynthia Gyamfi-Bannerman: Antenatal corticosteroid therapy for fetal maturation. Committee Opinion No. 713. *The American College of Obstetricians and Gynecologists.* *Obstet Gynecol* 2017; 130 : e102 – 9 .
7. E. Jauniaux et al., "FIGO classification for the clinical diagnosis of placenta accreta spectrum disorders," *International Journal of Gynecology and Obstetrics*, 2019; vol. 146, no. 1, pp. 20–24.
8. Lee, M.H., Ingvertsen, B.T., Kirpensteijn, J., Jensen, A.L. And Kristensen, A.T. Quantification of Surgical Blood Loss. *Veterinary Surgery*, 2006 35: 388-393
9. Dr. Ashraf Aly H. Dr. Hisham M. Ramadani, Assessment of Blood Loss During Cesarean Section Under General Anesthesia and Epidural Analgesia Using Different Methods. *Alexandria Journal of Anaesthesia and Intensive Care AJAIC-2006: Vol. (9) No. 1.*
10. John C. Kingdom, Sebastian R. Hobson, Ally Murji, Lisa Allen, Rory C. Windrim, Evelyn Lockhart, Sally L. Collins, Hooman Soleymani Majd, Moiad Alazzam, Feras Naaisa, Alireza A. Shamshirsaz, Michael A. Belfort, and Karin A. Fox, MMed Minimizing surgical blood loss at cesarean hysterectomy for placenta previa with evidence of placenta increta or placenta percreta *Am J Obstet Gynecol.* 2020 Sep; 223(3): 322–329.
11. Papillon-Smith J, Hobson S, Allen L, Kingdom J, Windrim R, Murji A. Prophylactic internal iliac artery ligation versus balloon occlusion for placenta accreta spectrum disorders: A retrospective cohort study. *Int J Gynaecol Obstet.* 2020 Oct;151(1):91-96.
12. Nieto-Calvache, Albaro José1,2,*; Palacios-Jaraquemada, José M.3; Aryananda, Rozi Aditya4; Basanta, Nicolás5; Burgos-Luna, Juan Manuel1,2; Rodríguez, Fernando1; Ordoñez, Carlos1; Sarria-Ortiz, Daniela6; Muñoz-Córdoba, Laura6; Quintero, Juan Carlos7,8; Galindo-Velasco, Valentina9; Messa-Bryon, Adriana1,2. Ligation or Occlusion of the Internal Iliac Arteries for the Treatment of Placenta Accreta Spectrum: Why Is This Technique Still Performed?. *Maternal-Fetal Medicine*:2023; 5(3):p 131-136.
13. Joshi VM, Otiv SR, Sovani YB, Kulat PK. Aortic clamping for limiting blood loss at cesarean hysterectomy for placenta percreta: A case series. *Int J Gynaecol Obstet.* 2022 May;157(2):289-295.
14. Paily VP, Sidhik A, Girijadevi RR, Sudhamma A, Neelankavil JJ, Menon UG, George R, Ramakrishnan S, Cheriyan S, John TE, Pradeep M. Managing placenta accreta spectrum in low-resource settings using a novel dissection-free aorta clamp: Operative technique. *Int J Gynaecol Obstet.* 2022 Aug;158(2):469-475.